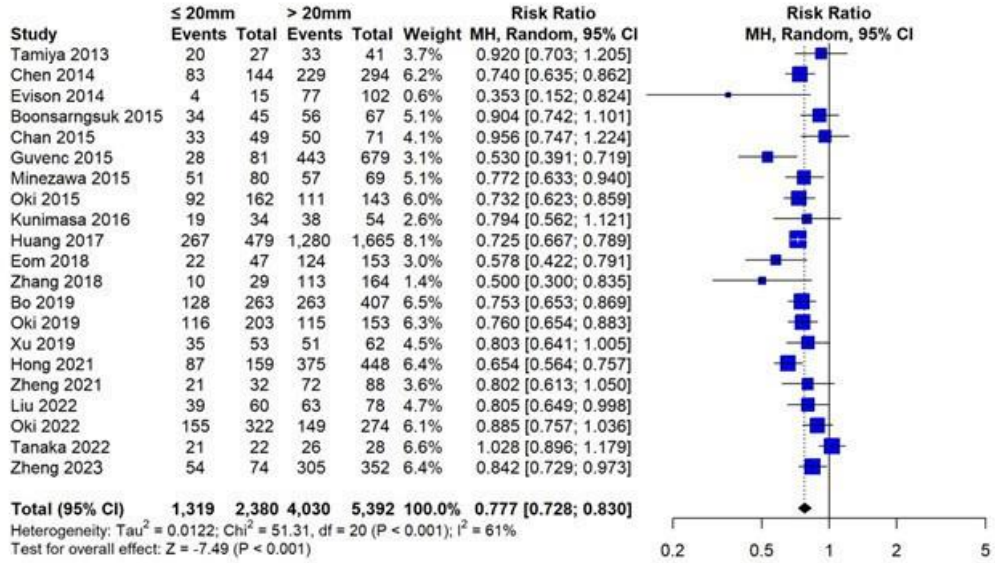
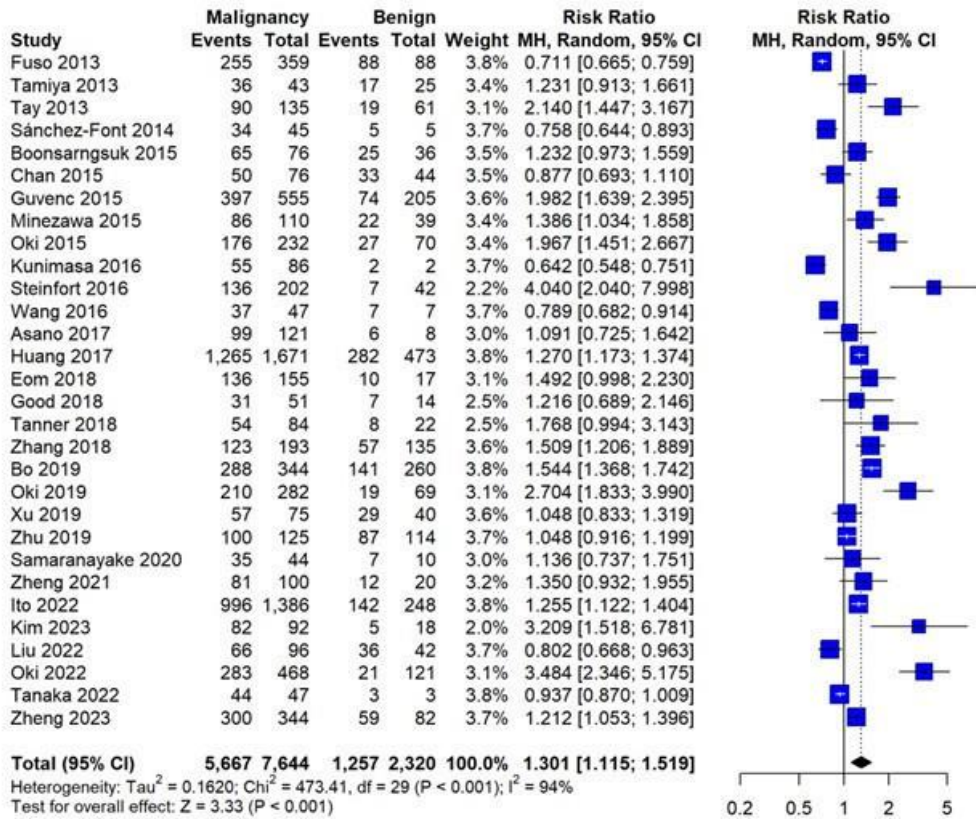
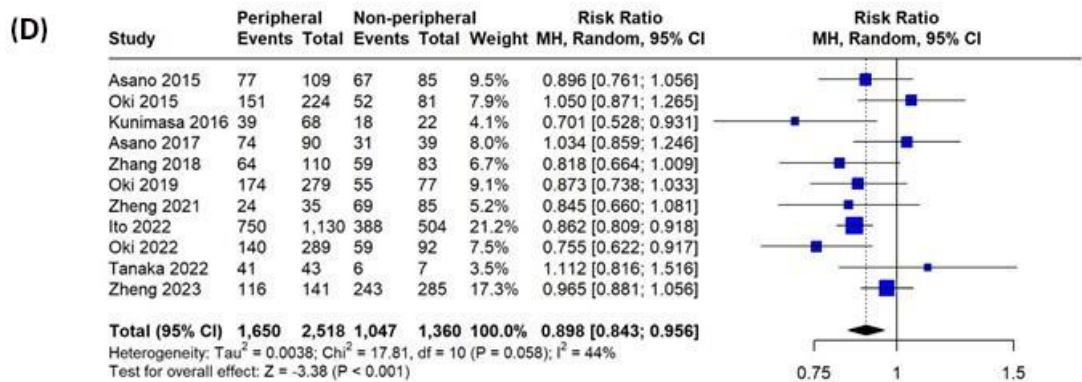
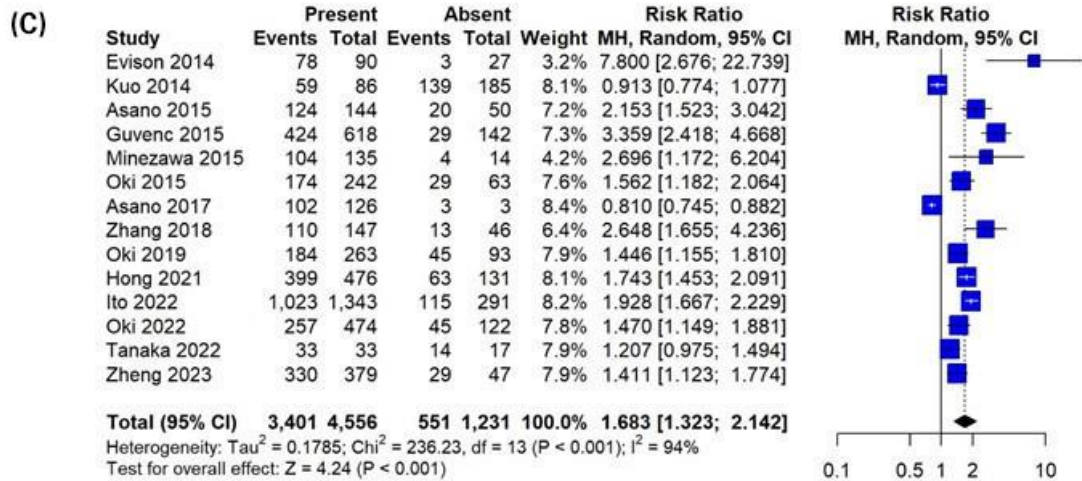


(A)



(B)





S3 Fig. Diagnostic yield of radial probe endobronchial ultrasound based on lesion size (A), histologic diagnosis (B), CT bronchus sign (C), and distance from the hilum (D) [1-13,15-24,26-28,30,32,34-36,38-41]. CI, confidence interval; MH, Mantel-Haenszel.